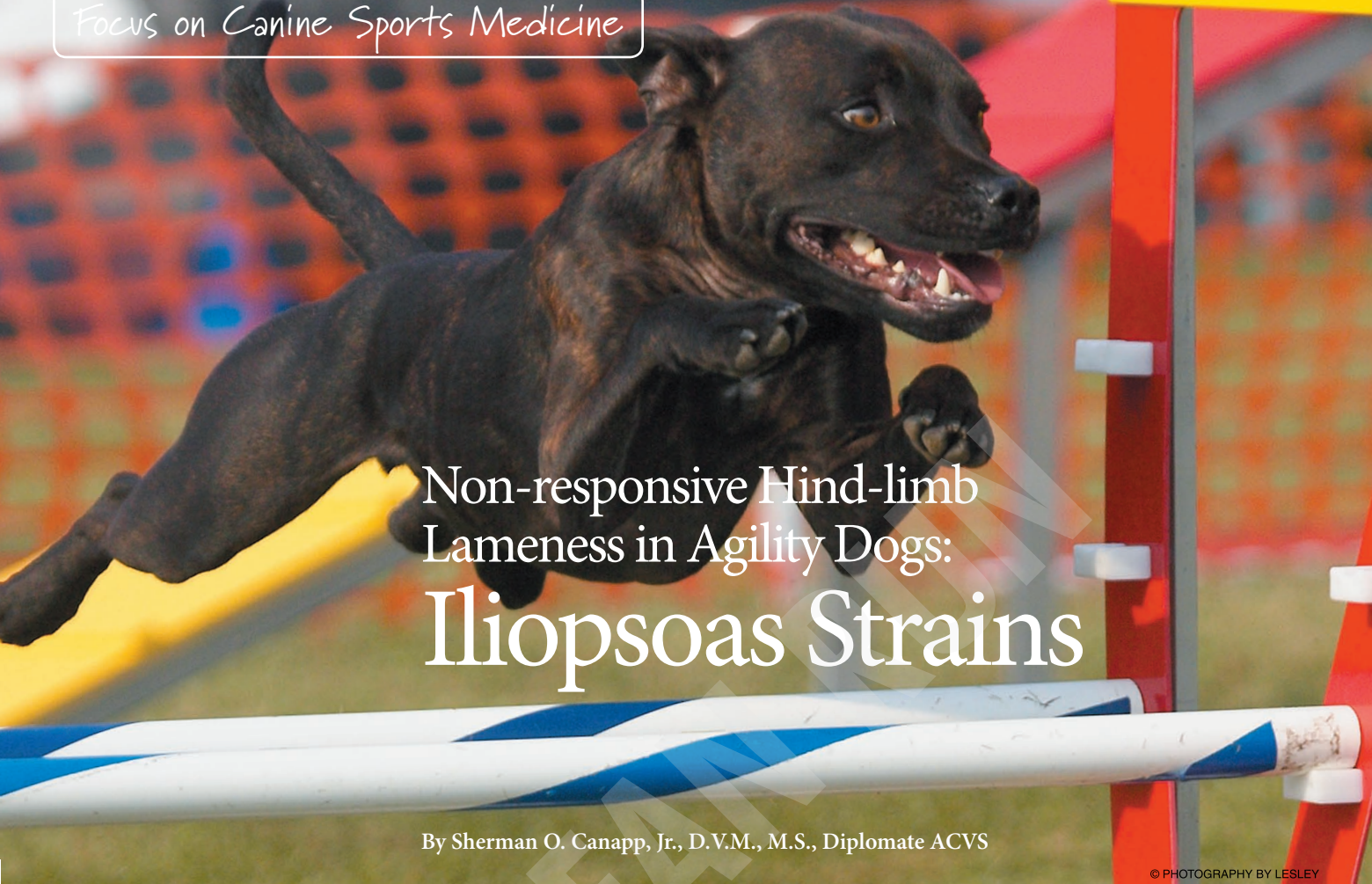

**THIS PAGE IS
INTENTIONALLY
BLANK**



Non-responsive Hind-limb Lameness in Agility Dogs: Iliopsoas Strains

By Sherman O. Canapp, Jr., D.V.M., M.S., Diplomate ACVS

© PHOTOGRAPHY BY LESLEY

Strider is a two-year-old intact female Border Collie. Over the past two months Strider had been having difficulty in agility runs, knocking bars with her hind limbs and slowing down in the weave poles. The trainer noticed that Strider was reluctant to fully extend her rear when going over jumps and was navigating with less force in the hind limbs when weaving. It was also noticed that Strider had a shortened stride in the right hind limb at a trot and would occasionally off-load and even toe-touch the right hind limb during the stance phase. Strider's owner had pulled her out of trials and after two weeks of rest, Strider's lameness appeared to improve. When the owner started practicing with Strider again, she cleared 16" jumps without any problem, but had difficulty clearing 20" jumps (Strider's jump height is usually 24"). Strider was once again pulled from training and the owner decided to have Strider examined by her veterinarian.

Strider's vet performed an examination, took x-rays of the hips and knees, and performed a Lyme disease test. The x-rays and blood work were within normal limits and Strider's veterinarian stated that it must be an early ACL injury. The veterinarian prescribed two weeks of Rimadyl (non-steroidal anti-inflammatory drug) and recommended that the owner continue to restrict Strider to leash walks only. Unfortunately, Strider had a limited response to two more weeks of rest and Rimadyl and the owner asked the veterinarian for a referral to a board certified orthopedic surgeon.

Strider was referred to me at our facility, the Veterinary Orthopedic & Sports Medicine Group (VOSM). At presentation, Strider had a mildly shortened stride in her right hind limb. During the stance phase Strider would occasionally off-load weight from her right hind limb to her other side. On physical examination Strider had mild atrophy (quads and hamstrings) in the right hind limb when compared to the

left. When the right hip was extended, abducted (moved away from the body), and internally rotated Strider showed signs of discomfort. When I applied gentle pressure to the iliopsoas muscle, I noted a significant spasm and trigger points. When pressure was applied to the iliopsoas's tendon and point of insertion on the lesser trochanter of the femur, Strider displayed significant discomfort. The remainder of the orthopedic and neurological examination was within normal limits. Based on the history and orthopedic examination I diagnosed Strider with an iliopsoas strain and recommended rehabilitation therapy (laser therapy, stretching and strengthening, and a home exercise program), medical management consisting of a muscle relaxant (Robaxin), and controlled activity. Following five days of Robaxin and six weeks of rehabilitation therapy and controlled activity Strider returned to training with no signs of lameness or performance issues, including returning to the 24" jump height.

> Iliopsoas Strains

Acute, stretching-induced muscle injuries are estimated to account for over 30% of injuries seen in a typical human sports medicine practice and have been reported to be the most common injury seen in human general practices. Acute muscle injuries have rarely been reported in the small animal veterinary literature, and discussion of chronic muscle disorders in dogs is limited to a handful of classical syndromes or inflammatory conditions. Given the similarities between the human and canine musculoskeletal system, it seems unlikely that such common injuries in human athletes would not also be common in the canine athlete. It is probable that the low reported prevalence of muscle injury in dogs is due to a failure to diagnose the condition.

Causes

Iliopsoas strains occur as the result of excessive force acting on this muscle, and are commonly associated with highly athletic activities such as agility. These injuries often occur at or near the muscle-tendon junction, which is the weakest part of the myotendinous unit. Eccentric contraction, in which the muscle is activated during stretch, is known to be an important factor in the development of these acute strain injuries. Traumatic incidents that result in active eccentric muscle contraction, such as slipping into a splay-legged position, jumping out of a vehicle, aggressive agility training, or roughhousing with other dogs are often suspected in precipitating acute lameness. It is not uncommon to find dogs with iliopsoas strains that have other concurrent orthopedic problems, or that have recently undergone surgical treatment for another orthopedic condition, such as cranial cruciate ligament rupture.

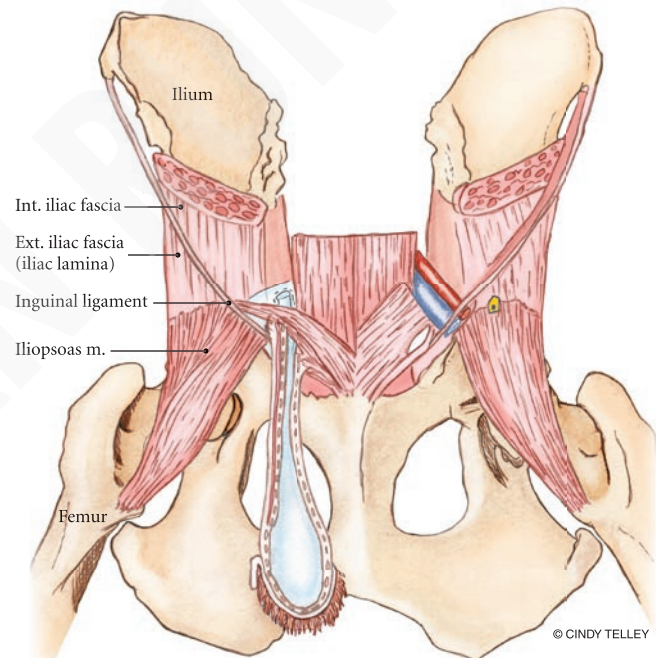
The iliopsoas muscle represents the fusion of the psoas major and the iliacus muscles as seen in the anatomy illustration. The psoas major muscle arises from the transverse processes of the lumbar vertebrae of the lower spinal column at L2 and L3 and the bodies of L4-7, and the iliacus arises from the ventral or lower surface of the ilium (or hipbone). The two muscles combine and have a common insertion on the lesser trochanter of the femur. The action of this muscle is to move the pelvic hind limb relative to the trunk via hip flexion, primarily moving the pelvic hind limb forward.

Diagnosis

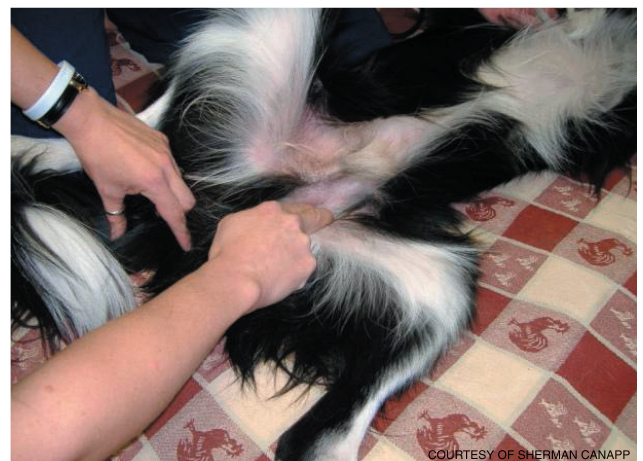Agility dogs with iliopsoas strains commonly present with a history of unilateral hind limb weight-bearing lameness that is exacerbated with activity. These dogs commonly demonstrate performance issues such as knocking bars with the hind limbs and slowing in the weave poles. The tendon of insertion of the iliopsoas can be palpated in a relaxed, friendly dog, where the femur meets the pelvis, at the very bottom of the “V” formed when the dog is lying on his back. Follow the femur down, as you palpate, down to the center of the V. That will be the lesser trochanter of the femur. The iliopsoas muscle is very deep, lying along the internal part of the ilium, or the hipbone, in the pelvis.



Signs of an iliopsoas strain may include a “tucked” position and lack of drive from the rear when weaving. A possible cause of an iliopsoas strain might be repeated jumping with extreme extension of the hind limbs (active eccentric muscle contraction) as shown by the photograph on the previous page.



Iliopsoas anatomy



The therapist locating/palpating the iliopsoas muscle-tendon unit along the inner thigh.

Get Started With Our 4-Jump Kit

includes all necessary pipe, fittings and jump cups to build 4 jumps that adjust from 3" to 35" in height

All the PVC You Need to Build It Yourself

4-Way Tee

Snap-On Jump Cups

5-Way Cross

PatiosToGo.com

352.243.3220

Furniture Grade PVC
Low Minimum Order • Box Quantity Discounts

vinyl tape for striping too!

On direct palpation, significant pain and spasm of the myotendinous unit may be noted. Pain and spasm will also be noted when stretching the myotendinous unit by either placing the hip in extension with abduction, or by simultaneous extension of the hip with internal rotation of that pelvic hind limb.

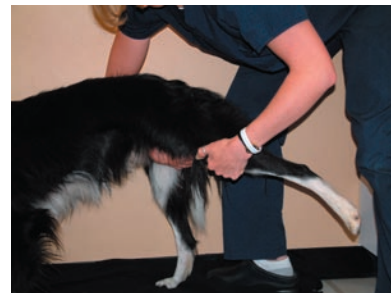X-rays are of little value in the early phase, but may reveal mineralization just cranial to the lesser trochanter in chronic cases. The use of advanced imaging modalities to demonstrate lesions of the affected muscle and/or tendon can increase confidence in the diagnosis. Ultrasonography is a relatively inexpensive noninvasive imaging modality for canine musculoskeletal evaluation with the additional advantage that general anesthesia is not required. This imaging modality is particularly dependent on the expertise of the operator, which may limit its practical application in some settings.

Advanced diagnostics such as CT (computerized tomography) scan and MRI (magnetic resonance imaging) may be used to identify iliopsoas strains and are both widely used in diagnosing acute, stretch-induced muscle injury in human patients. Although CT is valuable for imaging soft tissue lesions, the use of MRI has greatly increased the ability to detect submacroscopic lesions.

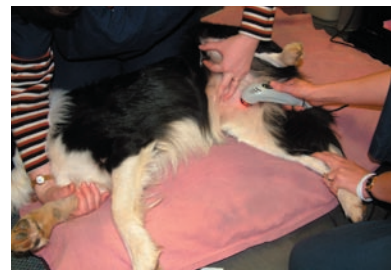Treatment

Acute iliopsoas strains should be treated conservatively. Skeletal muscle relaxants may be administered in severe cases to reduce pain and muscle spasms. Medical management may also include NSAIDs, cryotherapy (ice therapy) and controlled activity. Rehabilitation can be very effective in treating iliopsoas strains. Treatments may include laser therapy to increase circulation, remove waste products, and promote healing. Pain-free PROM (passive range of motion) and high-repetition exercise also are recommended. Acute strain injuries should not be stretched as microtears may occur. PROM, interferential e-stimulation, stabilization exercises, and gradual increases in weight bearing of the involved limb are recommended. Active ROM and strengthening exercises are added next. Strengthening exercises might include stepping over cavaletti poles, para standing (lifting both front and hind limbs on one side of the dog's body while he balances on the remaining limbs), paws on the counter, and use of the wobble board. Acupuncture may be helpful to assist with pain control and to promote healing.

In chronic iliopsoas strains, it is important to re-initiate the inflammatory process to assist in the remodeling of the tendon fibers. NSAIDs should be avoided with chronic iliopsoas strains as they impair the inflammatory response. Rehabilitation therapy is recommended with chronic iliopsoas strains. Modalities might include heat, ultrasound, and laser, followed by massage therapy. Be sure to check movement in the sacroiliac joint (SI joint) and lumbar region (lower spine). Chronic iliopsoas strains may come from a problem with mechanics, therefore, working on correcting the mechanics of movement, will help to take the strain off the iliopsoas and contribute to its healing. If you miss correcting movement mechanics, it may not get better. The exercise progression is similar to that for acute iliopsoas strains, but initiating stretching (hip extensors with abduction) after modalities and massage is advised as are longer walks. In chronic muscle strain injuries it usually takes longer to recover and progress through the stages of healing and exercise because of the chronic nature of the changes in the myotendinous unit. Education of owners/trainers is extremely important since they should be instructed to move the dog ahead slowly. When returning to agility training, weave poles and tight



This dog is in a stretch (extension of the hip with abduction and internal rotation). If pain is evident when stretching, the dog may have a strain.



The therapist treating the iliopsoas strain with laser therapy.

turns at full jump heights should be avoided during the early stages of retraining.

The risk of reinjury to a previously strained muscle is well established in human patients when a previous minor injury often predates a major strain injury. The risk of more significant strain is increased when pre-existing strain injury has not completely healed. This also appears to be the case in canine patients, in whom pain from iliopsoas strain injuries may recur.

Appropriate warm-ups, stretching, and retraining are extremely important in preventing injury and in returning your dog to a competitive performance level. Examples of retraining techniques for iliopsoas strains include starting with low, straight-line jumps, and later incorporating very wide sweeping turns that progress over time to higher jumps with tighter angles. Do not include higher jumps and weave poles until late in the retraining period. It has been well-reported that stretching without an appropriate warm up is detrimental to both the dog's tissues and his performance. In fact, it is much more important to do an

appropriate warm-up than stretching if time does not permit both. Following training and performance, make sure to implement iliopsoas stretching techniques (hip extension with abduction) and use an appropriate cool down with ice therapy (5 minutes on, 5 minutes off, 5 minutes on).

Surgical treatment is warranted for those that do not respond to conservative medical management and rehabilitation therapy. In these cases, where there are irreversible changes to the myotendinous unit, such as fibrosis (forming excess fibrous tissue while healing) of the muscle-tendon junction, surgical treatment by tenotomy/tenectomy (releasing the tendon) or reattachment may be indicated. Surgical intervention should be considered when the strain injury recurs at regular intervals or does not respond to medical treatment or rehabilitation therapy, although the lesion should be first confirmed with ultrasonography, CT, or MRI imaging. Good to excellent results have been reported with dogs returning to function although performance dogs may work at a lower level. 🐾

Additional Reading References:

- Nielsen C, Pluhar E. *Diagnosis and treatment of hind limb muscle strain injuries in 22 dogs.* 18:247-53, 2005
- Breur GJ, Blevins WE. *Traumatic injury of the iliopsoas muscle in three dogs.* J Am Vet Med Assoc 210:163-164, 1997
- Janssens LA. *Trigger points in 48 dogs with myofascial pain syndromes.* Vet Surg 20:274-8, 1991
- Kirkendall DT, Garrett WE. *Clinical perspectives regarding eccentric muscle injury.* Clin Orthop S81-9, 2002

Dr. Canapp, a Diplomate of the American College of Veterinary Surgeons completed a combined D.V.M./M.S. at Kansas State University, an internship in small animal surgery at the University of Missouri, a three-year residency in small animal surgery at the University of Florida, and training in canine rehabilitation by the Canine Rehabilitation Institute. Dr. Canapp currently practices orthopedic surgery and sports medicine at the Veterinary Orthopedic & Sports Medicine Group (VOSM) in Ellicott City, Maryland, and acts as a consultant to local zoos, police K-9 units, agility, flyball, and disc competition dogs. See additional information about Dr. Canapp at www.vetsportsmedicine.com.

Because he's not just a pet. He's an athlete.



Veterinary Orthopedic and Sports Medicine Group (VOSM) is committed to providing the highest quality veterinary Orthopedic surgery and rehabilitative care. VOSM is the only practice in North America with a:

- Board Certified Veterinary Orthopedic Surgeon trained in Canine Rehabilitation
- Veterinarian and Physical Therapist also trained in Canine Rehabilitation
- Veterinary Sports Trainer

Through the effective integration of science, compassion, and professional integrity, we relieve pain, regain movement, restore function, and promote health and wellness in your flourishing athlete. **We not only understand the demands that are placed on your athlete, we help him meet them.**

- Sports Medicine
- Minimally Invasive Orthopedic Surgery
- Gait Analysis & Retraining
- Rehabilitative Therapy

Entrust your best friend with the best in medical care.



10270 Baltimore National Pike Ellicott City, MD 21042 301-560-1397 or 410-418-8446 www.vetsportsmedicine.com